

GYNECOLOGY

International expert consensus on the surgical anatomic classification of radical hysterectomies



Denis Querleu, MD; David Cibula, MD; Nadeem R. Abu-Rustum, MD; Francesco Fanfani, MD, PhD; Anna Fagotti, MD, PhD; Luigi Pedone Anchora, MD; Manuel Maria Ianieri, MD; Vito Chiantera, MD; Nicolò Bizzarri, MD; Giovanni Scambia, MD

BACKGROUND: The anatomic descriptions and extents of radical hysterectomy often vary across the literature and operative reports worldwide. The same nomenclature is often used to describe varying procedures, and different nomenclature is often used to describe the same procedure despite the availability of guideline and classification systems. This makes it difficult to interpret retrospective surgical reports, analyze surgical databases, understand technique descriptions, and interpret the findings of surgical studies.

OBJECTIVE: In collaboration with international experts in gynecologic oncology, the purpose of this study was to establish a consensus in defining and interpreting the 2017 updated Querleu-Morrow classification of radical hysterectomies.

STUDY DESIGN: The anatomic templates of type A, B, and C radical hysterectomy were documented through a set of 13 images taken at the time of cadaver dissection. An online survey related to radical hysterectomy nomenclature and definitions or descriptions of the associated procedures was circulated among international experts in radical hysterectomy. A 3-step modified Delphi method was used to establish consensus. Image legends were amended according to the experts' responses and then redistributed as part of a second round of the survey. Consensus was defined by a yes response to a question concerning a

specific image. Anyone who responded no to a question was welcome to comment and provide justification. A final set of images and legends were compiled to anatomically illustrate and define or describe a lateral, ventral, and dorsal excision of the tissues surrounding the cervix.

RESULTS: In total, there were 13 questions to review, and 29 experts completed the whole process. Final consensus exceeded 90% for all questions except 1 (86%). Questions with relatively lower consensus rates concerned the definitions of types A and B2 radical hysterectomy, which were the main innovations of the 2017 updated version of the 2008 Querleu-Morrow classification. Questions with the highest consensus rates concerned the definitions of types B1 and C, which are the most frequently performed radical hysterectomies.

CONCLUSION: The 2017 version of the Querleu-Morrow classification proved to be a robust tool for defining and describing the extent of radical hysterectomies with a high level of consensus among international experts in gynecologic oncology. Knowledge and implementation of the exact definitions of hysterectomy radicality are imperative in clinical practice and clinical research.

Key words: cervical cancer, classification, gynecologic oncology, Querleu-Morrow, radical hysterectomy

Introduction

Cervical cancer ranks fourth in both incidence and cancer related mortality among women worldwide with 604,127 new cases diagnosed in 2020.¹ Open surgery is a mainstay of early-stage disease management.² The European Society of Gynaecologic Oncology (ESGO) has indicated that a description of the type of parametrial resection performed should be included in the surgical report as a quality indicator for the overall

improvement of clinical practice.³ Among the several available classification systems describing the extent of radical hysterectomies, the Querleu-Morrow (Q-M) classification has been adopted by the ESGO and the National Comprehensive Cancer Network.^{2,4} The original article describing the Q-M classification⁵ was among the top most co-cited papers in cervical cancer surgery between 2006 and 2022,⁶ reflecting surgeon interest in using standardized terminology and definitions to describe the extent of radical hysterectomy. Findings from a recent randomized educational study from Italy demonstrated the benefit of educational material to help consultants and residents better understand the extent of parametrial resection.⁷ The objective of the current study was to establish a consensus among a group of expert gynecologic oncologists in naming, defining, and interpreting the 2017

updated Querleu-Morrow classification of radical hysterectomies⁸ using anatomic images taken during cadaveric dissections.



Material and Methods

A program of cadaver surgery has been implemented at the anatomy laboratory of the Policlinico Agostino Gemelli IRCCS, Catholic University of Sacred Heart, Rome, Italy, for purpose of surgical teaching and standardization of surgical techniques. This study was approved by the Policlinico Agostino Gemelli IRCCS institutional review board on June 25, 2021 (number IST DIPUSVSP-25-06-2172). Anatomic photographs were taken at the time of 3 fresh-frozen cadaver radical hysterectomies mimicking the technique used in clinical practice with the objective to demonstrate the Q-M A, B, and C types of radical hysterectomy. The pictures were initially selected and approved by

Cite this article as: Querleu D, Cibula D, Abu-Rustum NR, et al. International expert consensus on the surgical anatomic classification of radical hysterectomies. *Am J Obstet Gynecol* 2024;230:235.e1-8.

0002-9378

© 2023 The Authors. Published by Elsevier Inc. This is an open access article under the CC BY license (<http://creativecommons.org/licenses/by/4.0/>).
<https://doi.org/10.1016/j.ajog.2023.09.099>

 Click Supplemental Materials under article title in Contents at 

AJOG at a Glance

Why was this study conducted?

Anatomic descriptions of radical hysterectomies are not standardized, which makes communication difficult and may bias research.

Key findings

A high level of consensus was reached (>90% agreement) among experts for the majority of the definitions on the extent of radical hysterectomies.

What does this add to what is known?

This study provides uniform terminology and original photographic documentation of agreed upon surgical steps.

the senior gynecologic oncology staff of Gemelli and then submitted to the authors of this paper. Finally, some pictures were replaced by clearer ones after the first round of the consensus process.

A total of 13 survey questions were created by the first and last authors, initially submitted to the senior staff of the Gemelli gynecologic oncology team, and then finalized after the first round of survey, taking into account experts' comments. Questions 1 and 2 addressed the excision line of the vesicouterine ligament; questions 3 to 5 addressed the lateral extent; and questions 6 and 7 addressed the excision line of the rectovaginal ligament. A second set of images was compiled to synthetically describe the different types of radical hysterectomy, namely type A (question 8), simple hysterectomy compared with type A (question 9), and types B (question 10), C (question 11), B2 (question 12), and C2 (question 13). Definitions corresponded to the 3-dimensional extent of the 2017 updated Q-M classification.⁸ Type D, which is essentially performed in the setting of recurrent disease, was not included in the survey. Anatomic nomenclature was based on recently published terminology.⁹

The survey was conducted using a commercially available online survey tool (SurveyMonkey, <https://www.surveymonkey.com/>) after email invitation. All questions were close ended with the only possible answers being yes or no and without option to abstain in response to the question, "do you agree?" The expert participants were allowed 150 words per question to offer suggestions

or to justify a no response. An expert in the field was defined as a gynecologic oncologist with experience in radical hysterectomy based on scientific reports, articles, and/or presentations in peer-reviewed forums. Personal contacts have been favored in order to geographically cover a variety of countries. Consensus was defined as the rate of yes votes for each question. The exact consensus rate is provided for each question.

A 3-step modified Delphi method was used to establish consensus. The first round of the survey was distributed between January 10, 2022, and February 15, 2022. Some experts expressed doubts about the wording and relevance of some questions or about the relevance of the picture to document their response. Their criticisms were taken into account and some questions or pictures were revised accordingly at the time of elaborating for round 2. Questions, figures, and figure legends that were revised based on the experts' feedback were submitted in a second round of the survey (the slideshow is available in the [Supplemental Material](#)) distributed between March 3, 2022, and June 15, 2022. Participant feedback was again used to address differing points of view and to reach a potential agreement. Participants were individually contacted for a third round via email in cases of unclear justification for a no response. Confirmed justifications for a no vote and additional technical or anatomical inputs were considered. Figure legends were amended accordingly and/or new photographs were taken at the time of an

additional cadaver surgery. The final figures and figure legends are presented in this paper.

Results

Of 48 experts approached for study participation, 30 (62.5%) accepted to participate, and of those, 29 of 30 (93.3%) completed the study. The final group of 30 experts were originally from Australia, Brazil, Canada, China, Colombia, France, Germany, Greece, Japan, Italy, Mexico, Spain, Sweden, Switzerland, the United Kingdom, and the United States. The list of experts can be found in the [Supplemental Material](#) section.

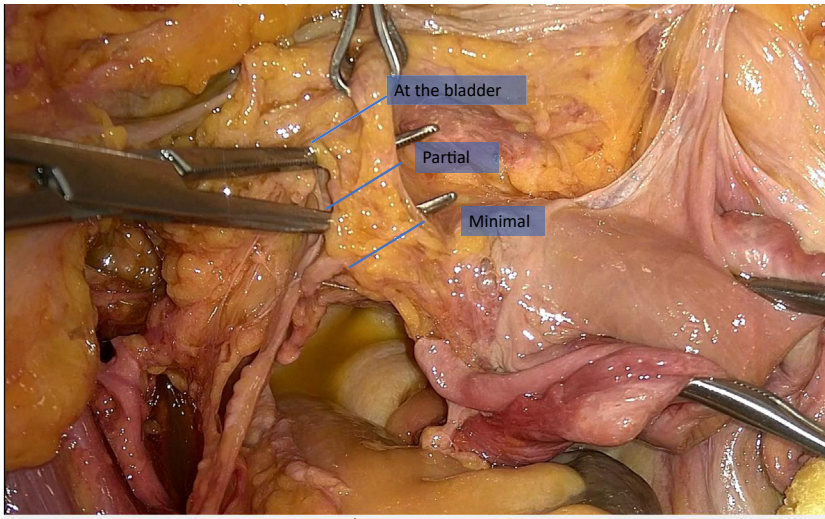
Ventral dissection: vesicouterine ligament

The ventral excision line defining a partial excision or excision at the bladder of the vesicouterine ligament ([Figure 1](#)) was approved by 26 (90%) and 28 (97%) experts, respectively. Justification for "no" responses for question 1 included "not sure what the question means" because the expert suggested to name the structure "medial vesicouterine ligament" and "this is type A." This comment can be interpreted in the context of the unclear difference between the minimal excision for a type A and partial excision for a type B radical hysterectomy as described in the 2017 Q-M update.⁸ Justification for a "no" response to question 2 was "like type B," meaning that the expert thought the vesicouterine ligament should be entirely excised in a type B radical hysterectomy.

Lateral dissection: paracervix or lateral parametrium

The lateral excision line halfway between the cervix and ureter for a type A ([Figure 2](#)), at the ureter for a type B, and at the iliac vessels for a type C radical hysterectomy were approved by 27 (93%), 29 (100%), and 27 participants (93%), respectively. Justification for the "no" responses included "type A is simple hysterectomy" (2 responses), "too much dissection for a type A" (2 responses), "this is already at the border with type C" (regarding the type B excision), "not clear" or "caudal limit

FIGURE 1
Excision lines of the vesicouterine ligament, left side



Querleu. Consensus on the classification of radical hysterectomy. *Am J Obstet Gynecol* 2024.

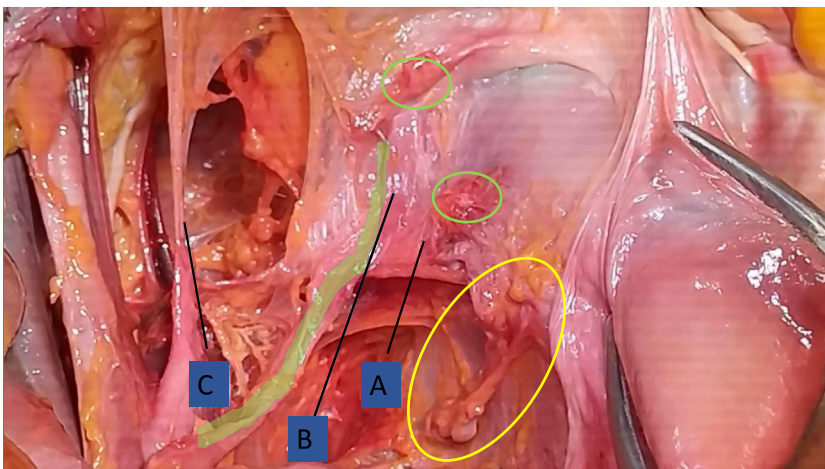
missing” (regarding type C), and a comment on terminology (“parauterine, not paracervix”).

Dorsal dissection: rectovaginal ligament

The dorsal excision line defining excision at the rectum or partial excision (Figure 3) of the rectovaginal ligament were approved by 27 (93%) and 25 participants (86%), respectively. The partial excision image was considered

unclear by 4 experts. The rest of the comments were related to nomenclature (“dorsal parametrium does not exist,” “at the distal uterosacral ligament”) or technique (“the ureter is not reflected enough”). One expert correctly indicated that the excision line of the rectovaginal ligament only, not including the autonomic nerves, corresponds exactly to a type C1 and not a type C radical hysterectomy in general.

FIGURE 2
Excision lines of the paracervix (lateral parametrium), left side



Querleu. Consensus on the classification of radical hysterectomy. *Am J Obstet Gynecol* 2024.

Extent of radical hysterectomy

The synthetic description of a type A radical hysterectomy (Figure 4, A) was approved by 26 experts (90%). The difference from a simple hysterectomy, sometimes referred to as an extrafascial hysterectomy, is that a simple hysterectomy does not include any paracervical or parauterine tissue, and this was approved by 28 experts (97%). Negative comments contested the concept of a type A radical hysterectomy (2 responses, 6%) and image (Figure 4, A) used (“too much dissection, no need to unroof the ureter”), highlighting that the image was intentionally taken after unroofing of the ureter in order to feature the anatomical landmarks, consequently not illustrating the practical surgical technique. Consequently, a photograph reproducing the actual surgery was taken (Figure 4, B). One participant and some of the authors expressed reservation regarding the need to remove the parauterine lymphovascular tissue.¹⁰

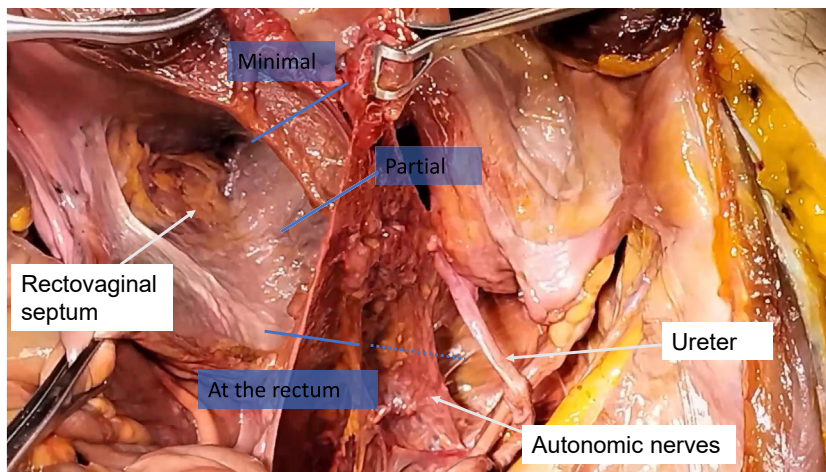
The synthesis of a type B radical hysterectomy (Figure 5) was approved by 28 participants (97%). Only 1 expert found the placement of the clamp to be too medial. The lateral definition of a type C radical hysterectomy (Figure 2) was approved by 29 participants (100%). The concept of paracervical lymphadenectomy underlying the type B2 radical hysterectomy (Figure 6) was approved by 26 participants (90%). The concept was found confusing by 2 experts, whereas 1 expert partially agreed but rated the picture negatively.

The Image of a type C2 radical hysterectomy (Figure 7) was approved by 28 participants (97%). The only negative response (3%) included a comment that the only important feature of radicality is the lateral extent and that the dorsal extent was of no importance.

Comment Principal findings

The main finding of this study is the high level of consensus on the radical hysterectomy Q-M classification and definitions of the extent of resection in all directions among renowned experts. The final consensus exceeded 90% for all questions except for 1

FIGURE 3
Excision lines of the rectovaginal ligament, right side



The line describing the excision line at the rectum includes a dotted line highlighting the possibility to spare the autonomic nerves.

Querleu. Consensus on the classification of radical hysterectomy. *Am J Obstet Gynecol* 2024.

(86%). The ideal outcome of this kind of study is to uniformize the surgical language, thus, the higher the consensus, the more reliable and usable the definition is.

Questions with relatively lower consensus rates concerned the definitions of type A and B2 radical hysterectomies. Of note, nearly all the negative comments of specific steps (questions 1–7) reflected thinking about the

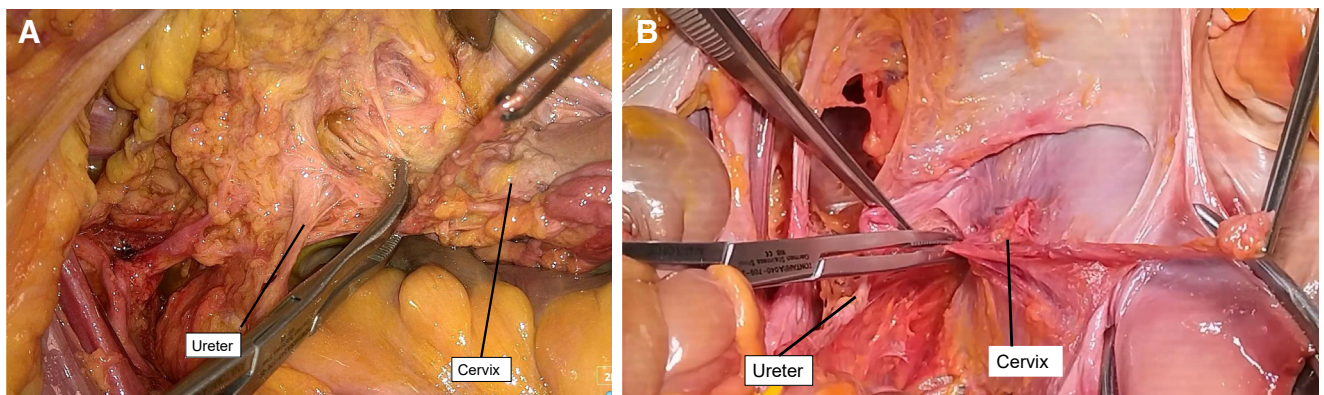
synthetic classification. This can be explained by the wording of the legends, for example, “Do you agree that the cutting line outlined by the forceps on the left vesico-uterine ligament at the level of the terminal ureter corresponds to ‘excision of the vesicouterine ligament at the bladder’ like in type C?” The pictures illustrating types A, B, and C reached a high level of consensus. In particular, types B1 and C prompted

minimal comments, and their definitions can be considered robust.

Results in the context of what is known

In contrast with a simple hysterectomy, also referred to as an extrafascial hysterectomy, a type A includes the removal of part of the paracervix close to the cervix, which justifies the term minimal radical. The type A radical hysterectomy is a more specific derivation of the type I hysterectomy as classified by Piver, Rutledge, and Smith (“Class I hysterectomy is not truly a radical hysterectomy but does extend beyond the excision boundaries of a conservative or standard hysterectomy”),¹¹ which does not specify the extent of removal. Type A also does not correspond to an extrafascial hysterectomy. Incidentally, extrafascial is a term that has been used for years to define a technique that ensures complete removal of the cervix. In this regard, an extrafascial hysterectomy is no more than a total hysterectomy. Actually, there is no fascia laterally, because there is continuity between the cervical stroma and the medial parts of the adjacent paracervix. In a type A abdominal radical hysterectomy, there is no need to deflect the ureter and separate it from its bed (Figure 4, B). In a limited type A vaginal radical surgery,

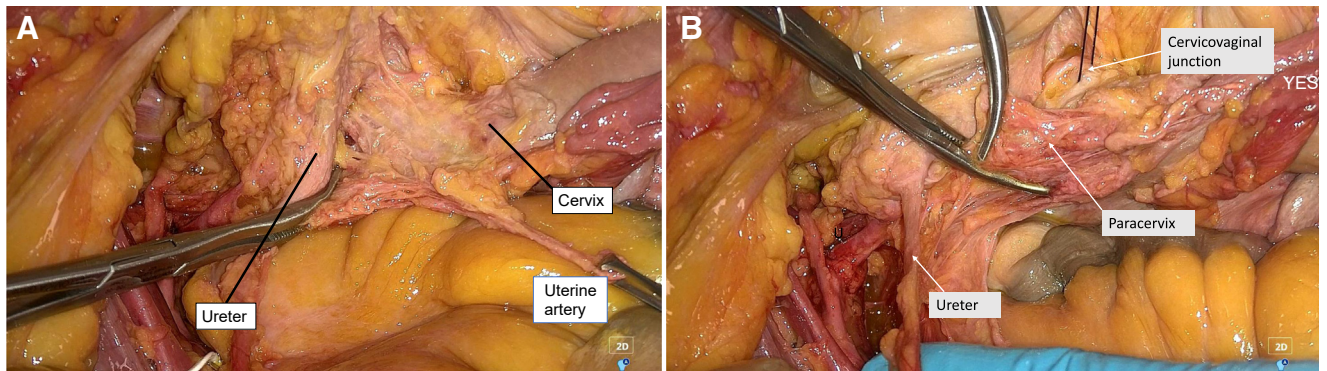
FIGURE 4
Radical hysterectomy type A



Anatomic definition after extensive dissection (A). Surgical practice definition in which the ureter has not been moved (B). In both pictures, (1) the clamp is placed half-way between the ureter and cervix, but some authors and experts consider that lateral radicality can be less, and (2) the uterine artery, along with the parauterine lymphovascular tissue, is excised (this component is not approved by all authors and experts, see text).

Querleu. Consensus on the classification of radical hysterectomy. *Am J Obstet Gynecol* 2024.

FIGURE 5
Radical hysterectomy type B



The clamp shows the anatomic position of the excision line (A). Care is taken to limit the excision to the paracervix caudally and to not include the paracolpos (B).

Querleu. Consensus on the classification of radical hysterectomy. *Am J Obstet Gynecol* 2024.

the course of the ureter is identified by palpation, and only a minimal part of the paracervix, maximum halfway between the cervix and ureter, is excised. The adjective maximum reflects the fact that in the real life, although the original classification arbitrarily defined type A as halfway, many users of the type A terminology believe that removal of only a small amount of paracervical tissue is enough to define type A. The bottom line is that the main goal is to remove the entire cervix along with at

least a minimum amount of paracervical tissue.

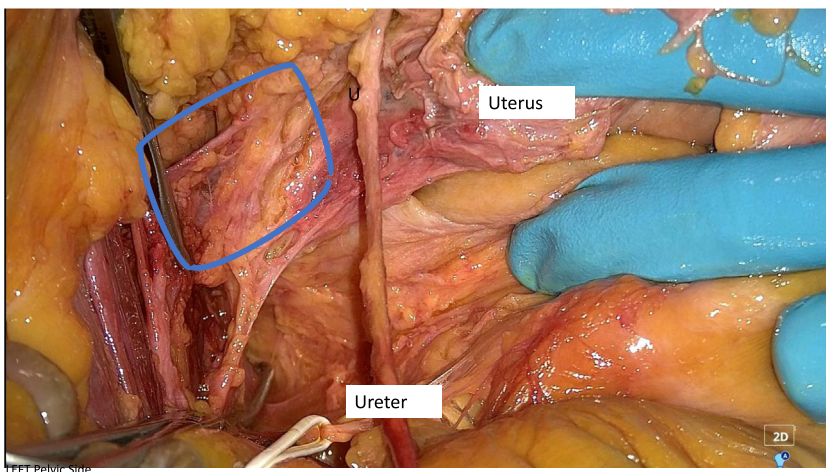
The additional removal of the recently identified parauterine lymphovascular tissue^{10,12} might be considered. This implies the division of the uterine artery at its origin, along with the superficial uterine vein and the upper anterior paracervical lymphatic pathway, which includes the most frequent lymphatic channel reaching the sentinel nodes and may contain metastatic nodes.¹⁰ However, the need

to specifically excise the parauterine lymphovascular tissue is not universally adopted by the authors and participating experts.

A type B2 radical hysterectomy is a derivative of the type B radical hysterectomy with the addition of a paracervical lymphadenectomy—removal of the lymph node-bearing tissue of the lateral part of the paracervix.¹³⁻¹⁴ The corresponding nodes are not removed at the time of a traditional pelvic lymphadenectomy during which the obturator nerves are caudal landmarks. The issue is that the use of the obturator nerve as the border between paracervical tissue and pelvic sidewall node-bearing tissue is arbitrary. A bilateral paracervical lymphadenectomy entails removal of the nodes ventral and dorsal to the internal iliac vessels, along with the nodes located between the lumbosacral trunks and the obturator nerves. In this regard, this procedure is no more than a comprehensive pelvic lymphadenectomy involving the lateral paracervical nodes. This can be achieved by blunt dissection, preserving the nerves (autonomic) and vessels (Meigs' web) that compose the lateral part of the paracervix.⁹ However, there is no evidence to suggest that the radicality of a type B2 radical hysterectomy is equivalent to that of a C1.

One expert contested the introduction of a 3-dimensional aspect in the updated Q-M classification, preferring to stick with the lateral definition of radicality.

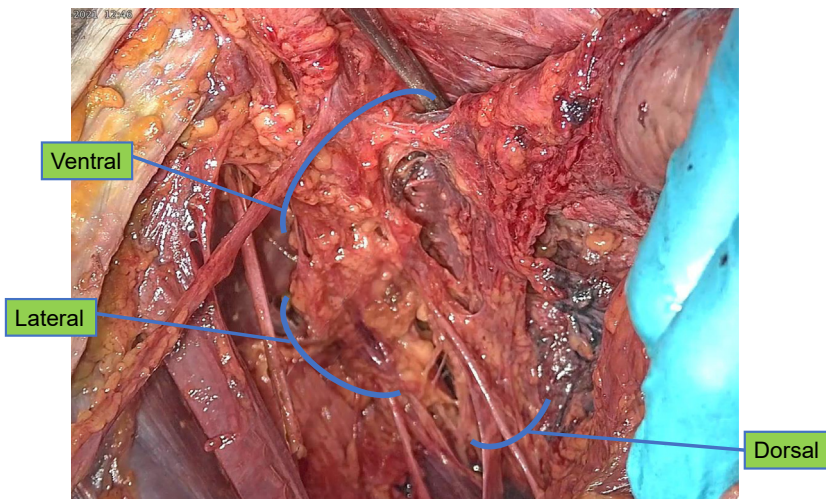
FIGURE 6
Site of paracervical lymphadenectomy, left side.



The blue box delineates the ventral part of the paracervical lymphadenectomy, the vessel, and nerve-sparing lymph node dissection of the lateral part of the paracervix, which defines a type B2 radical hysterectomy.

Querleu. Consensus on the classification of radical hysterectomy. *Am J Obstet Gynecol* 2024.

FIGURE 7
Radical hysterectomy type C2, left side



The blue lines show the excision lines in the lateral, ventral, and dorsal directions. The ureter has been fully mobilized.

Querleu. Consensus on the classification of radical hysterectomy. *Am J Obstet Gynecol* 2024.

However, if low-risk early cervical cancer does not extend ventrally and dorsally, this may be the case with tumors larger than 4 centimeter.¹⁵ In fact, the 3-dimensional aspect introduced by Cibula et al¹⁶ has been incorporated in the updated 2017 classification,⁸ complementing the extent of lateral resection with information on the extent in the dorsal and ventral directions and in the caudal direction for the paracervix. In contrast, the extent of vaginal resection has not been included in the classification. This is based on data showing that a wide vaginal margin is not needed¹⁷ in most surgically managed, early cervical cancers and that there is no reason to automatically link the length of vaginal resection to the lateral extent of radicality as is done in the Piver et al¹¹ classification system. In addition, the vaginal fornices and the cervix share the same lateral attachments, which makes the distinction between paracolpos and paracervix irrelevant in the upper vagina. However, it is clear that stage IIA cervical cancers require a radical colpectomy involving the removal of the real paracolpos or paracolpium, which is not mentioned in the original Q-M classification system. This missing part has been addressed recently by Muallem.¹⁸

Interestingly, 1 expert challenged the use of the ureter as a landmark on the basis that the ureter can be congenitally absent or displaced after a previous surgery, coincidental conditions, tumor size, or skeletonization. The latter is the most important issue, and the position of the ureter as the landmark must be determined before deflection.

Other experts noted the absence of details regarding the nerve-sparing technique, particularly the ways to separate the bladder nerves from the paracervix or paracolpos. However, a classification system is designed to set objectives and not to guide the ways to achieve them. The technical details of separation of the inferior hypogastric plexus and of the bladder nerves can be found in the literature.^{19,20} The bladder nerves are part of a structure traditionally referred to in Japan as the posterior leaf of the vesicouterine ligament, also named the vesicovaginal ligament by others.²⁰ This structure containing the vesical nerves and vesical veins actually has little anatomic relationship with the uterine corpus and remains lateral to the vagina to which it is only attached by the autonomic vaginal nerves and from which it can be separated by developing the paravaginal space.

It must also be highlighted that the preparation of the lateral spaces differs substantially across the various types, although all types have in common the need to open the lateral paravesical space for the purpose of lymph node assessment and the identification of the origin of the uterine artery and the deep uterine (or vaginal) vein thanks to the development of the medial paravesical space and the cephalic part of the lateral pararectal space. A type A radical hysterectomy does not require additional development of lateral spaces. The type B radical hysterectomy requires an opening of the medial pararectal space down to the level of the cervix and upper vagina, but not more in the caudal direction. Type C1 requires the full development of all 4 lateral spaces on both sides and the opening of the paravaginal spaces. In contrast, a type C2 radical hysterectomy does not require the development of the medial pararectal spaces and of the paravaginal spaces, as sparing the dorsal and ventral part, respectively, of the pelvic autonomic nerves is not an objective.

Clinical implications

The indications for each type of radical hysterectomy are not discussed in this paper. The purpose of a classification system is not to interfere a priori with management policy. The immediate clinical implication of this consensus report is the standardized description of the extent of cervical cancer surgery for the purpose of unbiased communication between physicians. Such standardization is required to compare outcomes in clinical practice and in retrospective studies, to design prospective studies, and, ultimately, to improve patient care. It is also a major tool that can be used to specify the content required by quality indicator 6 of the ESGO quality assurance list.³ In addition, all the other specialists involved in the multidisciplinary management of cervical cancer, especially oncologists and pathologists, should have a clear idea of the precise extent of the surgery planned and performed. Finally, the objective of this study, which was to avoid semantic

confusion at the time of future consensus on surgical and/or multidisciplinary strategy or of the design of any clinical controlled trial, was fulfilled. Any communication between clinicians should be based on a shared definition of the surgery performed.

Strengths and limitations

The main weakness of this study is the possible lack of varied expert representation. The study survey was completed by 29 expert gynecologic oncologists. There are more experts who were not on the list. At the same time, a universal criterium for expertise is not available, and a survey involving all the experts would not have been manageable. Other experts not included in this study may disagree with our consensus definitions.

However, the participating experts were not selected on the basis of their approval or personal use of the Q-M classification system. One expert even indicated a lack of consistency within his own group and country as a whole in which classification system they use. Section lines have been demonstrated by the placement of clamps. This could be considered as a weakness considering that the current surgical practice tends to use bipolar cautery and derived modern devices. However, the latter approach might have made it difficult to clearly demonstrate the goal of each specific step of excision in all directions. In addition, clamps are still in use in many institutions worldwide. In general, we acknowledge that cadaver surgery does not perfectly reflect real-life surgery, but performing this study during actual surgeries would be unethical considering the additional operative time, the increased risk of complications, and the modification of surgical steps in real time.

This study also has its strengths. A consensus among international experts likely led to definitions and educational material of higher quality than could have been achieved by a single team within a single institution alone. The experts also had extensive track records in performing and publishing on radical hysterectomy for the management of cervical cancer. Furthermore, the consensus process was adapted to include surgical issues, not just

anatomic issues, which remain confusing.²¹ The decision to modify the figures and legends after each survey round helped to improve the precision of the provided documentation. Contrary to other papers on classifications,^{11,22-24} this article features anatomic images instead of sketches and drawings, which invariably involve theoretical concepts.

Conclusion

Consensus on the classification of radical hysterectomies among a group of international experts was high. True standardization of surgical practice is an unachievable goal; however, this study demonstrates that the standardization of surgical definitions and descriptions, a topic of utmost clinical importance, can be achieved. Classification of radical hysterectomies must be based on anatomically and surgically relevant structures and must describe, with the most possible precision, the excision lines in all directions.^{23,24} Even the definitions of the original Q-M classification system required more discussion and fine tuning.^{4,8,16} This work provides documented standardization to define and describe the extent of the different Q-M types of radical hysterectomies by using surgical anatomic photographs with the overall goal of improving patient care and outcomes. ■

References

1. Sung H, Ferlay J, Siegel RL, et al. Global cancer statistics 2020: GLOBOCAN estimates of incidence and mortality worldwide for 36 cancers in 185 countries. *CA Cancer J Clin* 2021;71:209-49.
2. Cibula D, Raspollini MR, Planchamp F, et al. ESGO/ESTRO/ESP Guidelines for the management of patients with cervical cancer - update 2023. *Int J Gynecol Cancer* 2023;33:649-66.
3. Cibula D, Planchamp F, Fischerova D, et al. European Society of Gynaecological Oncology quality indicators for surgical treatment of cervical cancer. *Int J Gynecol Cancer* 2020;30:3-14.
4. Available at: <https://www.nccn.org/guidelines/guidelines-detail?category=1&id=1426>. Accessed October 16, 2023.
5. Querleu D, Morrow CP. Classification of radical hysterectomy. *Lancet Oncol* 2008;9:297-303.
6. Haibier K, Xu J, Sun C, et al. Global research trends on surgery in uterine cervical neoplasms: a bibliometric analysis via CiteSpace. *Research*

square. 2022. Available at: <https://doi.org/10.21203/rs.3.rs-1635222/v1>. Accessed October 16, 2023.

7. Genovese F, Siringo S, Tuscano A, et al. Understanding the limits of parametrial resection in radical hysterectomy: a randomized controlled trial. *Prz Menopauzalny* 2022;21:10-9.
8. Querleu D, Cibula D, Abu-Rustum NR. 2017 update on the Querleu-Morrow classification of radical hysterectomy. *Ann Surg Oncol* 2017;24:3406-12.
9. Querleu D, Bizzarri N, Fanfani F, Fagotti A, Scambia G. Simplified anatomical nomenclature of lateral female pelvic spaces. *Int J Gynecol Cancer* 2022;32:1983-8.
10. Lührs O, Ekdahl L, Geppert B, Lönnerfors C, Persson J. Resection of the upper paracervical lymphovascular tissue should be an integral part of a pelvic sentinel lymph node algorithm in early stage cervical cancer. *Gynecol Oncol* 2021;163:289-93.
11. Piver MS, Rutledge F, Smith JP. Five classes of extended hysterectomy for women with cervical cancer. *Obstet Gynecol* 1974;44:265-72.
12. Querleu D, Fanfani F, Fagotti A, Bizzarri N, Scambia G. What is paracervical lymphadenectomy? *Gynecol Oncol Rep* 2021;38:100891.
13. Querleu D, Leblanc E. Laparoscopic pelvic lymphadenectomy. In: Sutton C, Diamond M, eds. *Endoscopic surgery for gynaecologists*, 2nd ed. London, United Kingdom: Saunders; 1998. p. 407-16.
14. Querleu D, Narducci F, Poulard V, et al. Modified radical vaginal hysterectomy with or without laparoscopic nerve-sparing dissection: a comparative study. *Gynecol Oncol* 2002;85:154-8.
15. Landoni F, Bocciarelli L, Perego P, Maneo A, Bratina G, Mangioni C. Cancer of the cervix, FIGO stages IB and IIA: patterns of local growth and paracervical extension. *Int J Gynecol Cancer* 1995;5:329-34.
16. Cibula D, Abu-Rustum NR, Benedetti-Panici P, et al. New classification system of radical hysterectomy: emphasis on a three-dimensional anatomic template for parametrial resection. *Gynecol Oncol* 2011;122:264-8.
17. Piedimonte S, Helpman L, Pond G, et al. Surgical margin status in relation to surgical approach in the management of early-stage cervical cancer: a Canadian cervical Cancer collaborative (4C) study. *Gynecol Oncol* 2023;174:21-7.
18. Muallem MZ. A new anatomic and staging-oriented classification of radical hysterectomy. *Cancers* 2021;13:3326.
19. Fujii S, Takakura K, Matsumura N, et al. Precise anatomy of the vesico-uterine ligament for radical hysterectomy. *Gynecol Oncol* 2007;104:186-91.
20. Sakuragi N, Murakami G, Konno Y, Kaneuchi M, Watari H. Nerve-sparing radical hysterectomy in the precision surgery for cervical cancer. *J Gynecol Oncol* 2020;31:e49.
21. Zapardiel I, Ceccaroni M, Minig L, Halaska MJ, Fujii S. Avascular spaces in radical

hysterectomy. *Int J Gynecol Cancer* 2023;33:285–92.

22. Massi G, Savino L, Susini T. Three classes of radical vaginal hysterectomy for treatment of endometrial and cervical cancer. *Am J Obstet Gynecol* 1993;175:1576–85.

23. Trimbos JB. TNM-like classification of radical hysterectomy. *Gynecol Oncol* 2009;113:397–8.

24. Lee M, Choi CH, Chun YK, et al. Surgical manual of the Korean Gynecologic Oncology Group: classification of hysterectomy and

lymphadenectomy. *J Gynecol Oncol* 2017;28:e5.

Author and article information

From the UOC Ginecologia Oncologica, Dipartimento per la salute della Donna e del Bambino e della Sanità Pubblica, Fondazione Policlinico Universitario A. Gemelli, IRCCS, Rome, Italy (Drs Querleu, Fanfani, Fagotti, Anchora, Ianieri, Bizzarri, and Scambia); Charles University and General University Hospital, First Faculty of Medicine, Prague, Czech Republic (Dr Cibula);

Department of Surgery, Gynecology Service, Memorial Sloan Kettering Cancer Center, New York, NY (Dr Abu-Rustum); and Unit of Gynecologic Oncology, ARNAS Civico — Di Cristina — Benfratelli, Department of Health Promotion, Mother and Child Care, Internal Medicine and Medical Specialties (PROMISE), University of Palermo, Palermo, Italy (Dr Chiantera).

Received April 3, 2023; revised Sept. 23, 2023; accepted Sept. 25, 2023.

The authors report no conflict of interest.

Corresponding author: Denis Querleu, MD. denis.querleu@esgo.org